CANNT|ACITN
Canadian Association of Nephrology Nurses and Technologists
l'Association canadienne des infirmières et infirmiers et des technologues de néphrologie

CANNT JOURNAL
JOURNAL ACITN

Volume 28, Issue 2 April–June 2018

IN THIS ISSUE:

14 **CANNT 2018 Abstracts**

39 **Ultrasound evaluation of intraluminal needle position during hemodialysis: Incidental findings of cannulation complications**
By Rosa M. Marticorena, Latha Kumar, Jovina Concepcion Bachynski, Niki Dacouris, Ian Smith, and Sandra Donnelly

47 **CONTINUING EDUCATION SERIES**
Management of pain in patients on hemodialysis
By Rachel Liu and Marisa Battistella

CANNT|ACITN
Canadian Association of Nephrology Nurses and Technologists
l'Association canadienne des infirmières et infirmiers et des technologues de néphrologie

APRIL–JUNE 2018 • VOLUME TWENTY-EIGHT • ISSUE TWO

CANNT JOURNAL JOURNAL ACITN

CONTENTS

14 **CANNT 2018 Abstracts**

39 **Ultrasound evaluation of intraluminal needle position during hemodialysis: Incidental findings of cannulation complications**
By Rosa M. Marticorena, Latha Kumar, Jovina Concepcion Bachynski, Niki Dacouris, Ian Smith, and Sandra Donnelly

47 **CONTINUING EDUCATION SERIES**
Management of pain in patients on hemodialysis
By Rachel Liu and Marisa Battistella

IN EACH ISSUE:

4 Letter from the Editor: Jovina Bachynski

5 Notice Board

6 Mot de la rédactrice en chef : Jovina Bachynski

7 CANNT Representatives/ Contacts; Représentants/ contacts ACITN

8 Message from the President: Heather Dean

9 Message de la présidente : Heather Dean

10 Your Board in Action

12 Votre conseil en action

56 CANNT Membership

57 Guidelines for Authors

58 Lignes directrices à l'intention des auteurs

The CANNT Journal is printed on recycled paper.

Ultrasound evaluation of intraluminal needle position during hemodialysis: Incidental findings of cannulation complications

By Rosa M. Marticorena, Latha Kumar, Jovina Concepcion Bachynski, Niki Dacouris, Ian Smith, and Sandra Donnelly

Copyright © 2018 Canadian Association of Nephrology Nurses and Technologists

INTRODUCTION

Vascular access trauma due to poor needle placement can have serious consequences in the longevity of the vascular access. Complications such as infiltration or hematoma formation may be severe, causing delay or loss of dialysis treatment and/or may prolong catheter use. Cannulation complications may require treatment interventions, thus increasing the burden of illness in patients on hemodialysis (HD) and adding to the cost burden on the healthcare system (Lee, Barker, & Allon, 2006; Marticorena, Dacouris, & Donnelly, 2018).

Although ultrasound use has become the standard of care in many HD units around the world, its use in guided cannulation is limited to cannulation of new or complicated accesses. Cannulation of an arteriovenous (AV) access for hemodialysis (HD) is routinely performed using physical assessment techniques (i.e., observation, auscultation, and palpation) (Brouwer, 2011) without ultrasound assistance (i.e., blind cannulation) (Schoch, Du Toit, Marticorena, & Sinclair, 2015). After cannulation, the position of the needle inside the vessel lumen is manually tested with a 10 mL syringe with normal saline. If there is no resistance during aspiration or infusion of saline, the needles are secured with tape, and dialysis is initiated ((Brouwer, 2011; Marticorena et al., 2018). The prescribed blood flow (300–450 mL/min) is expected to be attained within a few minutes of starting the HD treatment. If there are no machine access alarms, the assumption is that the needle is in the optimal position inside the vessel lumen.

When an access alarm is triggered, the blood pump stops and dialysis is interrupted. After confirmation that there is no infiltration, the needle is then "repositioned" (i.e., manipulated by changing its direction and angle of penetration, or rotating the bevel) until dialysis can be resumed. Needle repositioning is a common dialysis procedure that needs to be performed with excellent technique to prevent mechanical trauma by accidental laceration of the endothelia or piercing through the vessel wall (i.e., backwalling) (Brouwer, 2011; Dinwiddie, Ball, Brouwer, Doss-McQuitty, & Holland, 2013). During HD, blood flow disturbances that occur at needle sites (generated by the jet stream from the venous needle) increase as the pump speed (Qb) increases (Marticorena & Donnelly, 2016). In vitro studies have shown that the hemodynamic trauma caused by the force of the jet stream against the access wall causes endothelial cell denudation, decrease in nitric oxide (Huynh et al., 2007; Unnikrishnan et al., 2005), and activation of biochemical cascades that induce development of neointimal hyperplasia (NIH) and stenotic lesions, which, ultimately, may result in flow obstruction, thrombosis, and access loss (Roy-Chaudhury, 2005; Roy-Chaudhury, Arend, et al., 2007; Roy-Chaudhury, Spergel, Besarab, Asif, & Ravani, 2007). Needles pointing to the anterior wall in the arteriovenous fistula (AVF) during HD can result in high intensity jet stream and turbulence directed to the near vessel wall (Tuka, Wijnen, van der Sande, & Tordoir, 2009). Therefore, an optimal position in the centre of the vessel lumen is critical to minimizing mechanical trauma (caused by accidental laceration of the endothelia or piercing through the vessel

AUTHOR NOTE

Rosa M. Marticorena, BScN, RN, DCE, PhD(C), Institute of Medical Science, University of Toronto, Clinical Research Coordinator III, Nephrology Research Offices, St. Michael's Hospital, Toronto, ON and William Osler Health System, Brampton, ON

Latha Kumar, MScN (Ed), RN, Dialysis Access Coordinator, William Osler Health System, Brampton, ON

Jovina Concepcion Bachynski, MN, RN(EC), Vascular Access Coordinator, William Osler Health System, Brampton, ON

Niki Dacouris, BSc(Hons), Research Coordinator, St. Michael's Hospital, Toronto, ON

Ian Smith, MD, FRSC, Vascular Surgeon, Department of Surgery, William Osler Health System, Brampton, ON

Sandra Donnelly, MDCM, MSc, FRCP(C), Nephrologist, William Osler Health System, Brampton, ON, Assistant Professor, University of Toronto, Toronto, ON, Scientist, Li Ka Shing Knowledge Institute, St. Michael's Hospital, Toronto, ON

Latha Kumar and Jovina Concepcion Bachynski are currently at Halton Healthcare, Oakville, ON

Address for correspondence: *Rosa M. Marticorena, William Osler Health System, 2100 Bovaird Dr. East, Brampton, ON L6R 3J7. Tel: 905-494-2120 ext. 57989; email:* ***rosamyrna.marticorena@williamoslerhs.ca***

wall) and hemodynamic trauma attributable to blood turbulence during dialysis (by directing the jet flow stream to the centre of the vessel lumen). When dialysis takes place without access alarms, the needle is assumed to be in the optimal position inside the vessel lumen. The objective of this study was to explore the accuracy of the assumption of optimal needle placement in the centre of the access lumen during HD with blind, uncomplicated cannulations.

METHOD

Design

We conducted an observational study to obtain ultrasound imaging of intraluminal needle position in patients receiving hemodialysis. The study received approval from the institutional research ethics board. This study was part of a larger study that compared metal needle versus plastic cannula in the development of complications at cannulation sites in hemodialysis vascular access (Marticorena et al., 2018) and was conducted by a single advanced operator (Marticorena et al., 2015) during ultrasound training of nursing staff.

Participants

A total 115 patients were evaluated from May 2013 to April 2014. The subjects' participation diagram is presented in Figure 1. A list of all prevalent patients receiving chronic HD treatment with an AV access was generated; these patients were evaluated only once and in sequence while attending treatment at their routine dialysis stations. They were classified in three groups: (1) patients who underwent uncomplicated cannulations (n=86); (2) patients who required needle repositioning (n=23); and (3) patients who required re-cannulation (more than two needle insertions) (n=6).

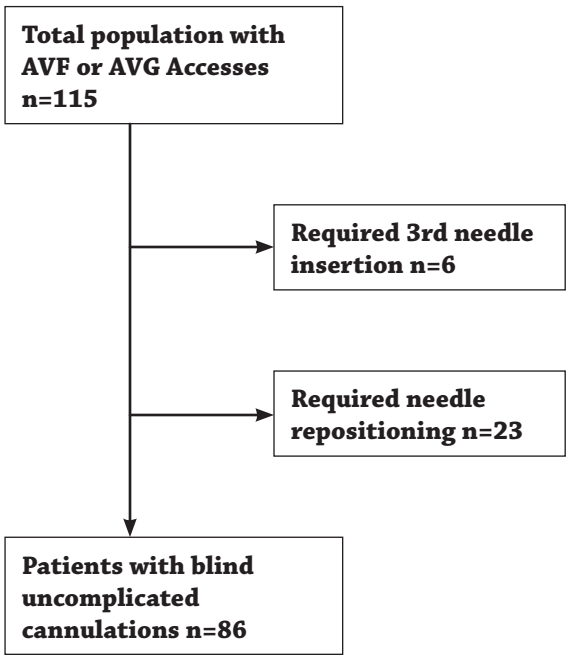

Figure 1. Subject Participation Flow Diagram

Intervention

Ultrasound evaluations of intraluminal needle position were performed in patients who underwent successful cannulations (i.e., one arterial needle and one venous needle) without ultrasound guidance (blind cannulation) and who had achieved the prescribed pump speed without interruption. All cannulations were performed by a total of 68 nursing staff with hemodialysis experience ranging from one to 22 years. Evaluations were conducted within 30 minutes of starting HD treatment. Patients with problematic cannulations received ultrasound assistance for needle repositioning or re-cannulation, and were not included in the intraluminal needle position analysis.

The needle devices used for cannulation during the study were: 1-inch or 1.25-inch 15-gauge metal needles (Nipro Corporation) and 1-inch or 1.25-inch 17-gauge plastic cannulae (Medikit, Supercath). Ultrasound evaluations were performed with the ultrasound systems SonixTouch (Ultrasonix Medical Corporation, Richmond, BC, Canada) or SonoSite S-Cath (Sonosite Canada, Markham, Ontario).

The proximity of the arterial and venous needles, and the presence of the securing tape between the two needles allowed for evaluations at the venous needle sites alone. Images were taken in short and long axes, and measurements of depth and diameter were obtained. Needle positions were classified as "anterior" (body of the needle resting against the anterior wall) (Figure 2), "posterior" (needle tip touching the back wall) (Figure 3), and "centre" (needle tip free in the centre of the vessel lumen) (Figure 4).

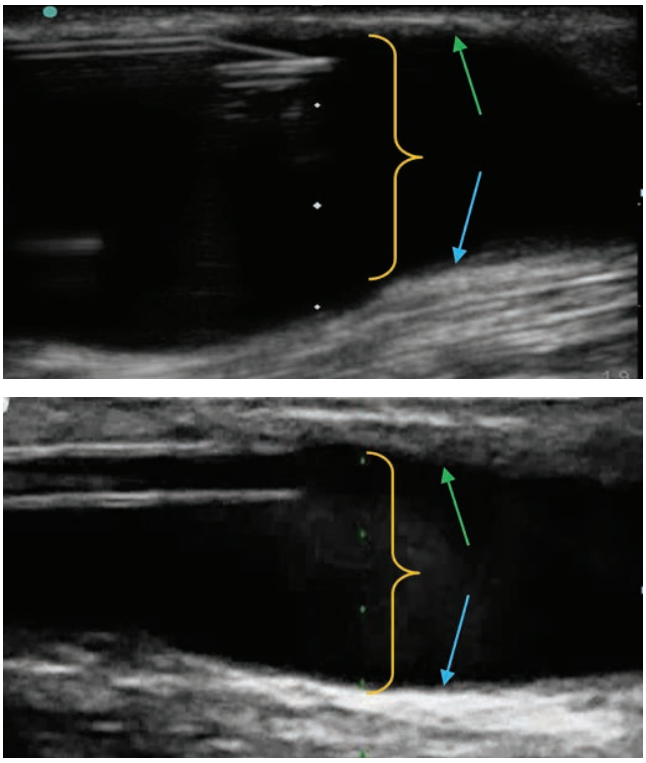

Figure 2. Anterior position (anterior wall) with metal needle with bevel up (top) and plastic cannula (bottom): anterior wall (green arrows), posterior walls (blue arrows), and intraluminal space (orange brackets)

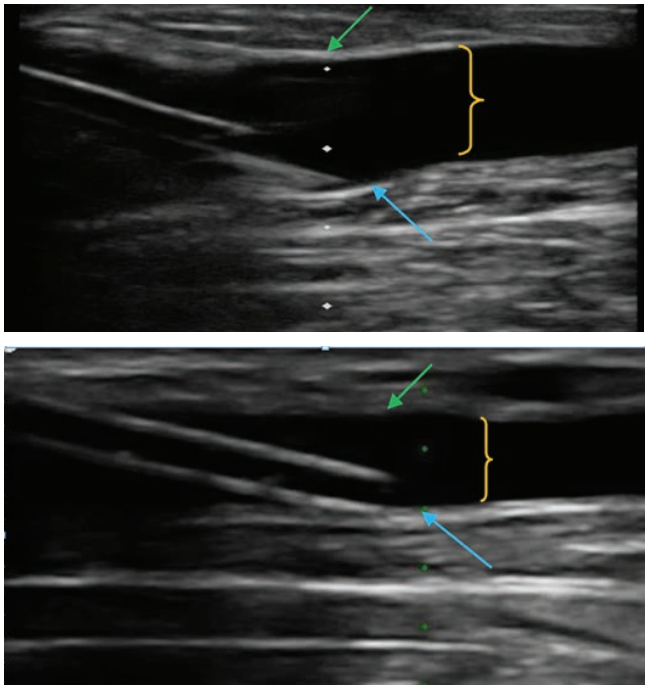

Figure 3. Posterior position (back wall) with metal needle (top) and plastic cannula (bottom): anterior wall (green arrows), posterior wall (blue arrows), and intraluminal space (orange brackets)

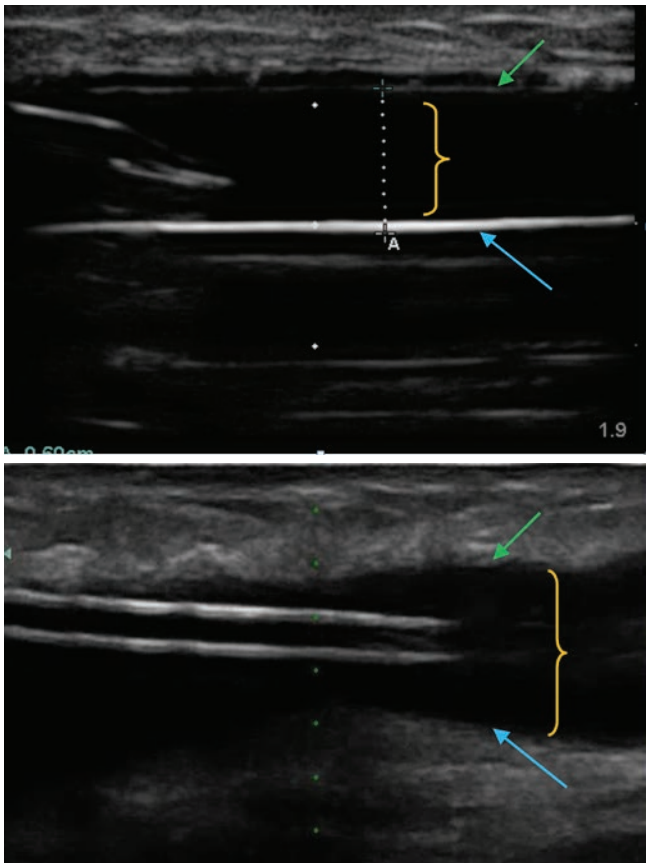

Figure 4. Centre position with metal needle with bevel up (top) and plastic cannula (bottom): anterior wall (green arrows), posterior wall (blue arrows), and intraluminal space (orange brackets)

STATISTICAL ANALYSIS

Descriptive statistics were used to present baseline demographic and clinical characteristics including age, gender, dialysis vintage, and access vintage in the study group. Normally distributed data are presented with means and standard deviations. Analysis of variance was used to compare differences between the three groups. Categorical data are presented as frequencies (percentages) and compared using chi-squared differences for proportions. Data that did not have a normal distribution were compared using the Wilcoxon signed-rank test. Statistical software IBM SPSS statistics for Windows (Version 22.0. Armonk, NY. IBM Corp.) was used for all statistical analyses in this study.

RESULTS

Baseline characteristics of the patient population are shown in Table 1. There were 86 patients in total, 50 (58.1%) males and 36 (41.9%) females. Sixty-eight patients (79.1%) had upper arm accesses and 18 (20.9%) patients had lower arm accesses. A total of 53 needles (61.6%) were in anterior wall position, 25 (29.1%) in posterior wall position, and 8 (9.3%) in the centre of the access lumen.

Table 1. *Patient Baseline Characteristics*

	N=86	%
Baseline Characteristics:		
Male	50	58.1%
Female	36	41.9%
Mean Age (yrs)	65.3 (13.9)	
Mean HD Vintage (mo)	24.6 (18.8)	
Mean Access Vintage (mo)	34.5 (132.2)	
Upper Arm Access	68	79.1%
Lower Arm Access	18	20.9%
Arterio-venous Fistula	82	95.3%
Arterio-venous Graft	4	4.5%
Cause of Renal Disease:		
DM	48	55.8%
Glomerulonephritis	10	11.6%
HTN/Vascular	17	19.8%
Other	11	12.8%
Needle Position:		
Anterior	53	61.6%
Posterior	25	29.1%
Centre	8	9.3%

(± Standard Deviation [*SD*] in brackets)

Table 2. *Distribution of Depth and Diameter by Needle Location*

Depth	Anterior	Centre	Posterior	Total
0.6 cm or less	26 (43.3%)	5 (9.1%)	24 (43.6%)	55 (64%)
0.7 cm or less	27 (87.1%)	3 (9.7%)	1 (3.2%)	31 (36%)
Diameter	**Anterior**	**Centre**	**Posterior**	**Total**
0.5 cm or less	3 (42.9%)	0 (0%)	4 (57.1%)	7 (8.1%)
0.6 cm or less	50 (61.6%)	8 (10.1%)	21 (26.6%)	79 (91.9%)

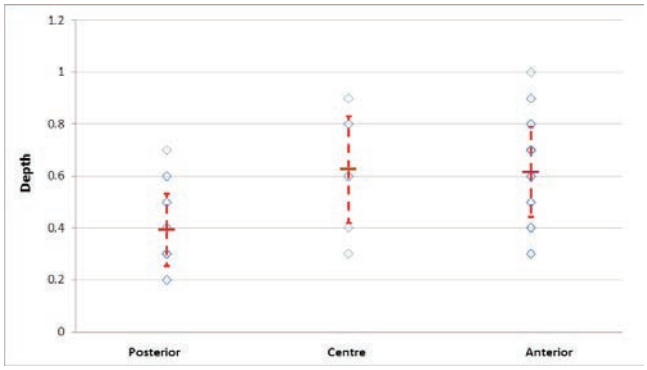

Figure 5. Needle Position by Access Depth

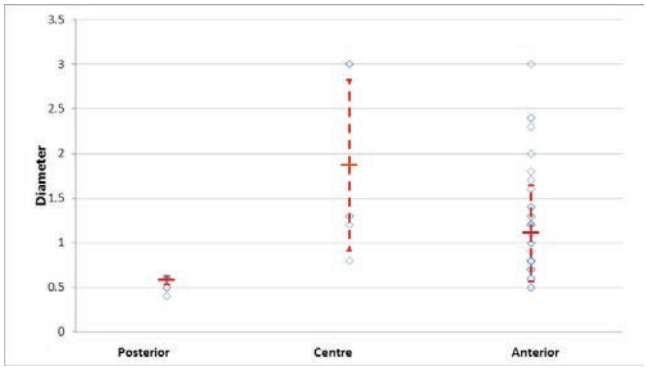

Figure 6. Needle Position by Access Diameter

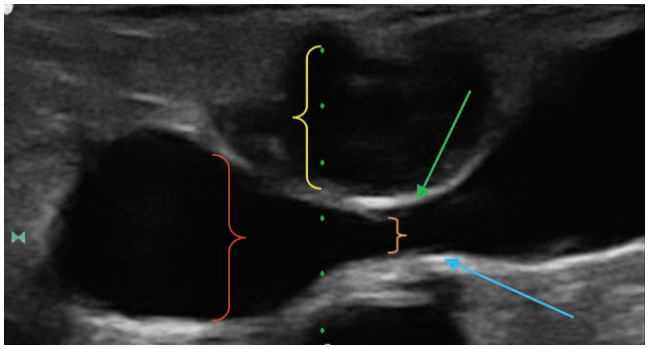

Figure 7. Anterior localized hematoma showing vessel wall distortion (yellow bracket shows the hematoma compressing the anterior vessel wall) and marked narrowing of intraluminal vessel diameter (orange bracket) compared to baseline intraluminal vessel diameter (red bracket)

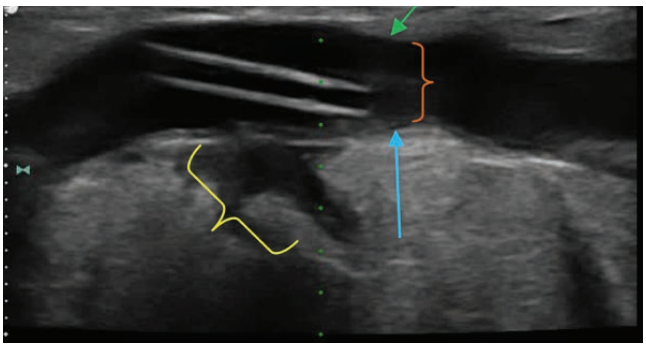

Figure 8. Posterior wall blood extravasation (yellow bracket): anterior wall (green arrow), posterior wall (blue arrow), and intraluminal space (orange bracket)

The distribution of depth and diameter by needle location is shown in Table 2. Accesses were further stratified by depth and diameter, using the depth and diameter K/DOQI criteria for cannulation (depth ≤ 0.6 cm and diameter ≥ 0.6 cm). Seventy-nine (91.9%) access diameters were ≥ 0.6 cm, and 55 (64%) access diameters were located at ≤ 0.6cm of depth from the skin surface.

Association Between Access Depth and Intraluminal Needle Position

There was an association between deep accesses (0.7 cm or more from the skin surface) and anterior needle position, this association was statistically significant ($p<.001$) (Figure 5).

Association Between Access Diameter and Intraluminal Needle Position

There was no association between accesses with small diameters (0.5 cm or less) or accesses of diameters of 0.6cm or more, and needle position ($p=1.0$) (Figure 6).

Incidental Findings of Cannulation Complications

Blood infiltrations of various sizes and configurations were identified at the cannulation sites (Figures 7 and 8). Needles piercing the back walls of an arterio-venous fistula (AVF) (Figures 9a and 9b) and an arteriovenous graft (AVG) (Figures 10a and 10b) were found in two patients. Pseudoaneurysms at the cannulation segments were identified in two subjects: One was located in the anterior wall of an AVG

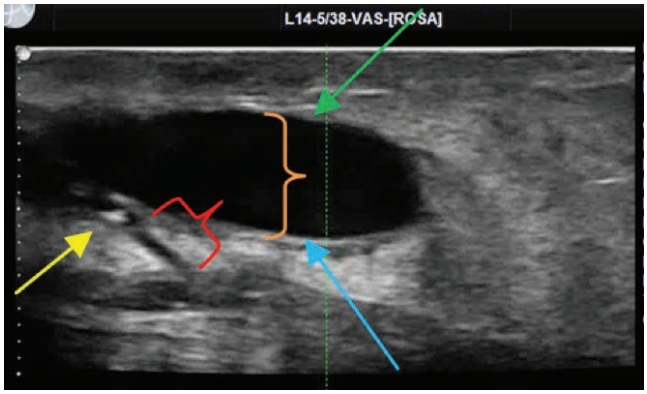

Figure 9a. Metal needle tip (yellow arrow) piercing a posterior fistula wall. Red bracket shows needle tract left after needle retraction. Green arrow points at the anterior AVF wall, blue arrow points at the posterior AVF wall, and orange bracket captures the diameter of the intraluminal space

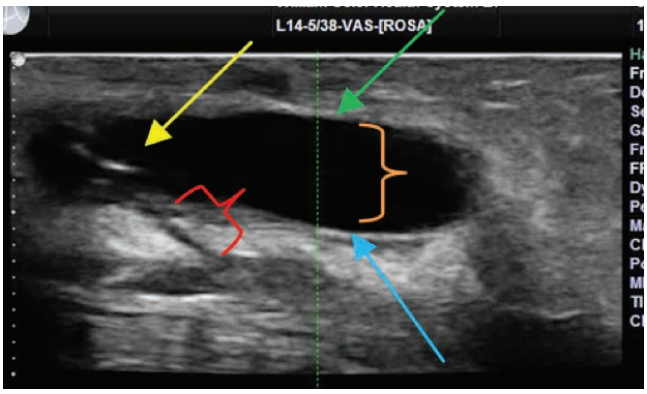

Figure 9b. Needle retracted into the intraluminal space (yellow arrow points at the needle tip)

(Figure 11a), and one was located at the lateral wall in an AVF (Figure 11b). Distinct image patterns of the jet flow stream in the intraluminal space were observed in metal needles (Figure 12a) and plastic cannula (Figure 12b).

DISCUSSION

This study showed that our assumption of needle placement in the centre of the vessel lumen with blind cannulation was correct only 9.3% of the time. These results have important implications related to mechanical and hemodynamic trauma to the inner lining of the access wall. Evaluations were performed in cannulations reported as uncomplicated, in one single stroke, and without any needle manipulation by nurses with a wide range of years of experience. Patients were receiving their treatments at their prescribed Qb, with pressures within expected ranges. In practice, alarm-free dialysis initiation indicates an optimal needle position with the jet stream from the venous needle directed to the centre of the vessel lumen flowing free of obstacles (i.e., a venous valve) or barriers (i.e., needle against the vessel wall).

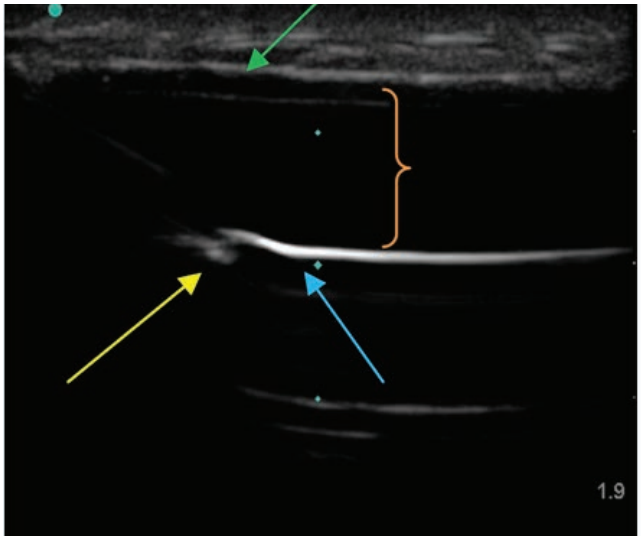

Figure 10a. Metal needle tip piercing a posterior graft wall: needle tip (yellow arrow), anterior wall (green arrow), posterior wall (blue arrow), and intraluminal space (orange bracket)

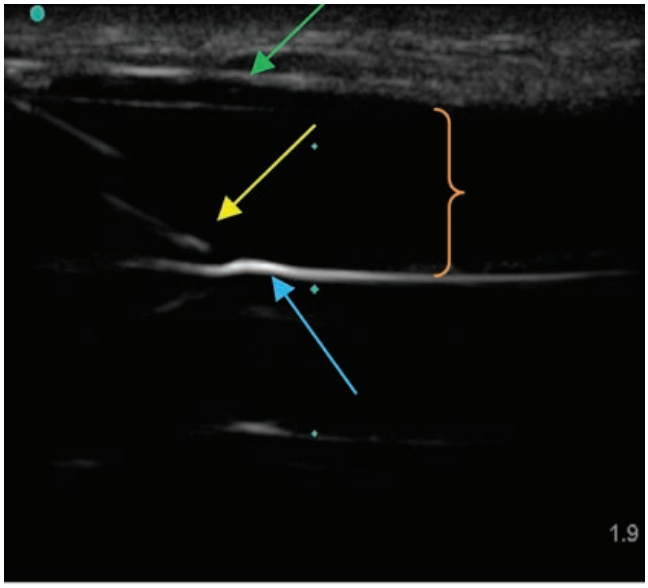

Figure 10b. Needle retracted into the arterio-venous graft intraluminal space (yellow arrow points at the needle tip)

In this study, we found that 61.6% (n=53) of the needles were in the anterior position regardless of the access depth, diameter, or depth and diameter combined together. In most cases, this was a result of the securing tape pressing the metal needle butterfly wings or the hub of the plastic cannula against the patient's access. With the needle against the anterior wall, the jet stream flows parallel to the anterior wall. The force of the jet flow stream against the endothelia for the duration of dialysis may be responsible for most of the NIH and stenotic lesions that develop at cannulation sites, which may develop at a fast pace if needle rotation in the cannulation segment is limited. In vitro models (Huynh et al., 2007; Unnikrishnan et al., 2005) and fluid dynamic computational simulation models of

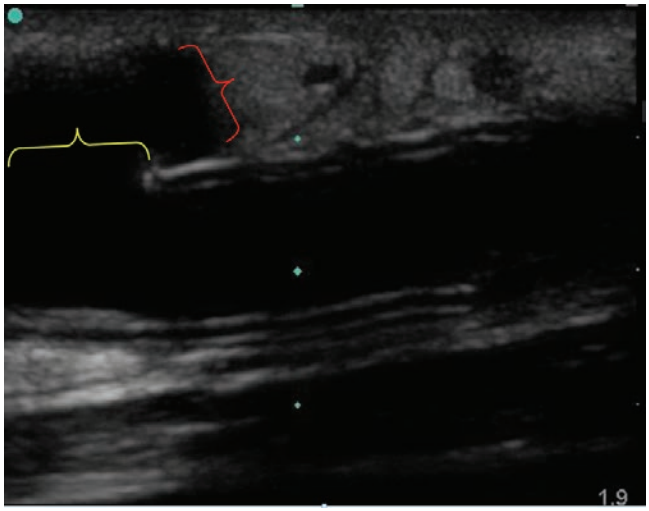

Figure 11a. Anterior graft wall destruction (yellow bracket) with pseudo-aneurysm formation (red bracket). Graft anterior and posterior walls (green brackets) and white arrows point at the two hyperechoic parallel bands characteristic of a prosthetic arterio-venous graft. Yellow dashed parallel lines show the area where the anterior graft is absent

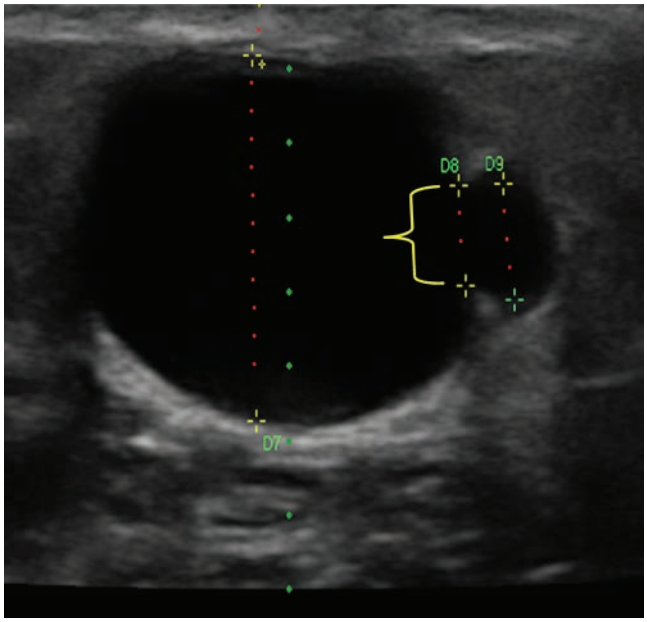

Figure 11b. Fistula showing depth of 2.07 mm from the skin surface (6D) and diameter of 12.27 mm (7D). The neck of the pseudo-aneurysm (yellow bracket) measures 3.38 mm (8D). It has a lateral wall pseudo-aneurysm with a diameter of 3.92mm (9D). Calipers are shown in yellow and connecting points are shown as red dash lines

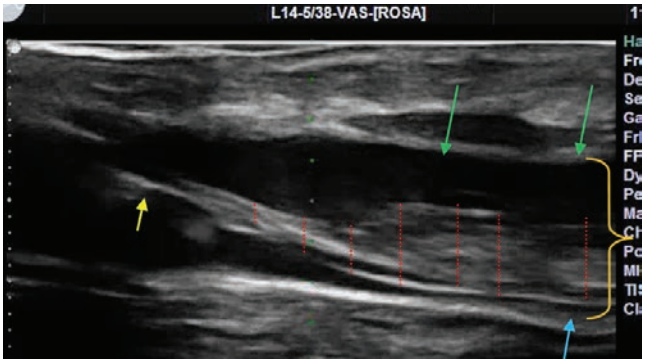

Figure 12a. Metal needle in centre position: Jet flow stream of normal saline is directed from the needle tip to the posterior vessel wall spreading downstream (red dashed lines). Yellow arrow points at the bottom tip of the metal needle; green and blue arrows point at the anterior and posterior vessel walls, respectively. The orange bracket encloses the intraluminal space

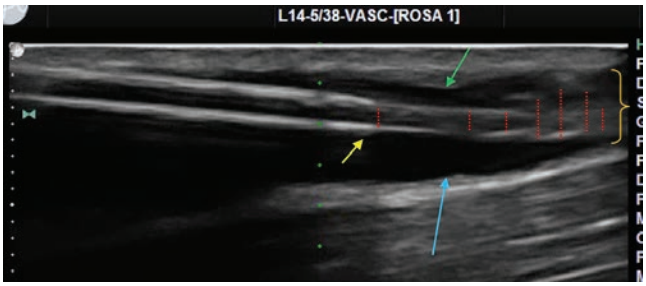

Figure 12b. Plastic cannula in centre position: Jet flow stream of normal saline is directed from the tip of the cannula to the centre of vessel lumen spreading downstream (red dashed lines). Yellow arrow points at the bottom tip of the cannula; green and blue arrows point at the anterior and posterior vessel walls, respectively; and orange bracket encloses the intraluminal space.

the hemodynamic effect of intraluminal needle position consistently indicate that shallow angles of the jet stream injection coming from the venous needle (<30 degrees) and slower pump speeds (Qb 250 mL/min) during HD minimize wall shear stress and produce the lowest blood flow disturbances and inherent endothelial damaging effect when compared to steeper angles (>30 degrees) and higher pump speeds (Qb >300 mL/min) (Barber, Fulker, Lwin, & Simmons, 2015; Fulker, Kang, Simmons, & Barber, 2013; Fulker, Simmons, & Barber, 2016; Fulker, Simmons, Kabir, Kark, & Barber, 2016; Yang, Yin, & Liu, 2017). These studies are consistent with clinical findings of increased turbulence in patients receiving hemodialysis in which mean Doppler velocities were shown to increase with increasing Qb at venous needle sites during HD (Marticorena & Donnelly, 2016; Tuka et al., 2009). Although a slower Qb might be an option for slow and long dialysis treatments (i.e., nocturnal hemodialysis), it is not an option in standard four-hour HD treatments in which Qb prescriptions of 350-400 mL/min are usually required to achieve adequate dialysis treatments.

A centre needle position is thought to be ideal when one considers the potential for mechanical trauma that may be caused by the sharp edge of a metal needle during cannulation, or during needle repositioning. Only 9.3% of needles in our study population were located in the centre position. Flow image patterns in devices in the centre position showed distinct patterns when using a plastic cannula (Figure 12a) or metal needle (Figure 12b). The metal needle jet stream was directed to the posterior wall, compared to being directed to the centre of the vessel lumen when using plastic cannulae. These observations require randomized clinical trials to determine the long-term effect of blood turbulence at needle sites, comparing metal needles and plastic cannula for HD. Twenty-nine percent (n=25) of the needle tip devices were in the posterior position. In this position, in addition to the effect of the flow injection stream on the back wall, the effect of mechanical trauma of the needle tip against the access wall was evaluated. Three levels of needle engagement were observed and classified as mild (i.e., needle tip resting on the back wall without vessel wall distortion), moderate (i.e., needle pushing the back wall with vessel wall distortion [tenting observed in AVF only]), and severe (i.e., needle tip piercing through the access wall). The unexpected findings of two cases of severe needle engagement, in which patients had no discomfort and the dialysis machine venous pressures were within parameters, caused much surprise and a new concern. One can wonder how many times "backwalling" occurs during blind cannulation or needle repositioning, and goes unnoticed. This concern may be supported by the finding of a needle tract extending from the needle tip where "backwalling" had already occurred and had left the needle mark extending from the back wall (Figure 9a); blood extravasation through this path may go unnoticed if not severe enough to cause vessel wall distortion as the one observed in Figure 7. This type of diffuse blood collection resolves slowly, surfacing to the skin over a few days. This may explain some instances in which a patient returns for their next dialysis treatment with a bruised access without any apparent reason for it. This emphasizes the importance of applying steady pressure with a tourniquet to prevent anterior wall collapse during needle insertion, as well as taking extreme caution when needle repositioning is done without ultrasound assistance (Brouwer, 2011; NKF-K/DOQI, 2006).

Superficial accesses (0.6cm or less from the skin surface) with diameters of 0.6 cm in posterior position may be at higher risk of endothelial damage when needle repositioning is required to maximize Qb. In this type of an access, cannulation with plastic cannula might need to be considered as an option to minimize the risk of accidental laceration of the endothelia or needle infiltration.

Anterior wall hematomae, located above the anterior access wall, were palpable only if they were localized (Figure 6). Diffuse hematoma was not palpable. Posterior wall hematomae, with or without vessel wall distortion, were not palpable (Figure 7) even in cases of posterior vessel wall distortion. Without visualization, posterior wall distortion might go unnoticed until severe enough to be detected by a marked change in sound at auscultation accompanied by difficult cannulations and/or the inability to reach the prescribed Qb. The altered geometry of the intraluminal space caused by hematoma compression will produce altered local hemodynamics (increased velocities) in the narrow, compressed areas until the hematoma resolves. The effect of altered hemodynamics in the interdialytic period caused by cannulation complications needs to be further studied.

LIMITATIONS

This study has the following limitations: First, the evaluations were done only once within 30 minutes of the initiation of dialysis. The possibility exists that the needle tip might have changed position inside the lumen as patients tend to rotate and or bend their arms intermittently for comfort during treatment. A second limitation is that only venous needle evaluations were obtained. The effect of the hemodynamic disturbances with negative pressures at arterial needle sites is different from the positive pressure caused by the venous jet stream; this needs to be studied in the clinical setting. Venous needle flow injection patterns can be visualized at the start of HD with "direct connection." The agitated micro-bubbles of oxygen contained in the normal saline provide contrast to allow ultrasound visualization of the flow, as it enters the intraluminal space through the venous needle. The turbulence that occurs at arterial needle sites with the blood being pulled into the dialysis circuit cannot be visualized as the blood flowing is visualized only in black with B-mode ultrasound (or in brightness mode that displays a two-dimensional image in black, white, and a few shades of grey in the screen). Turbulence at the arterial needle site may have a different effect in the access wall compared to the venous needle site.

Periodic ultrasound assessments in accesses that are reported as "problem-free" might be required to detect access complications at an early stage. The practical aspects of ultrasound use for routine cannulation or intermittent assessment of uncomplicated accesses needs to be further studied. Availability of less-expensive, portable, and user-friendly devices is needed at the bedside; only then will we be able to ensure that needles are in their optimal position during hemodialysis.

Complications related to needle insertions are common, and most patients have at least one within a few weeks of the use of the access. A success rate of only 9% for all HD treatments in the first six months of use has been reported with cannulations without ultrasound assistance (van Loon, Kessels, van der Sande, & Tordoir, 2009), compared to 85% success for all cannulations guided by ultrasound in incident and prevalent vascular accesses over a mean follow-up of approximately 10 months (Marticorena et al., 2018). The practical aspects of using ultrasound for all cannulations require further scientific evaluation.

To our knowledge, this is the first study that shows that the assumption of needle placement in the centre of the vessel lumen is correct only approximately 10% of the time with standard blind cannulation. The clinical impact of the long-term effect of the three types of intraluminal needle positions described in this study in the development of complications at cannulation sites with the two types of needle devices for cannulation of dialysis accesses warrants further exploration.

REFERENCES

Barber, T., Fulker, D., Lwin, N.M., & Simmons, A. (2015). Using fluid dynamics to improve vascular access in haemodialysis. *Renal Society of Australasia Journal, 11*, 32–34.

Brouwer, D.J. (2011). Cannulation Camp: Basic needle cannulation training for dialysis staff. *Dialysis & Transplantation, 40*(10), 434–439. doi:10.1002/dat.20622

Dinwiddie, L.C., Ball, L., Brouwer, D., Doss-McQuitty, S., & Holland, J. (2013). What nephrologists need to know about vascular access cannulation. *Seminars in Dialysis, 26*(3), 315–322. doi:10.1111/sdi.12069

Fulker, D., Kang, M., Simmons, A., & Barber, T. (2013). The flow field near a venous needle in hemodialysis: A computational study. *Hemodialysis International, 17*(4), 602–611. doi:10.1111/hdi.12029

Fulker, D., Simmons, A., & Barber, T. (2016). Computational model of the arterial and venous needle during hemodialysis. *Journal of Biomechanical Engineering, 139*(1), 011005-011005-011007. doi:10.1115/1.4034429

Fulker, D., Simmons, A., Kabir, K., Kark, L., & Barber, T. (2016). The hemodynamic effects of hemodialysis needle rotation and orientation in an idealized computational model. *Artificial Organs, 40*(2), 185–189. doi:10.1111/aor.12521

Huynh, T.N., Chacko, B.K., Teng, X., Brott, B.C., Allon, M., Kelpke, S.S., ... Anayiotos, A.S. (2007). Effects of venous needle turbulence during ex vivo hemodialysis on endothelial morphology and nitric oxide formation. *Journal of Biomechanics, 40*(10), 2158–2166.

Lee, T., Barker, J., & Allon, M. (2006). Needle infiltration of arteriovenous fistulae in hemodialysis: Risk factors and consequences. *American Journal of Kidney Diseases, 47*(6), 1020–1026.

Marticorena, R.M., & Donnelly, S.M. (2016). Impact of needles in vascular access for hemodialysis. *Journal of Vascular Access, 17*(Suppl. 1), S32–S37. doi:10.5301/jva.5000534

Marticorena, R.M., Mills, L., Sutherland, K., McBride, N., Kumar, L., Concepcion-Bachynski, J., ... Donnelly, S.M. (2015). Development of competencies for the use of bedside ultrasound for assessment and cannulation of hemodialysis vascular access. *Canadian Association of Nephrology Nurses and Technologists Journal, 25*(4), 28–32.

Marticorena, R.M., Dacouris, N., & Donnelly, S.M. (2018). Randomized pilot study to compare metal needles versus plastic cannulae in the development of complications in hemodialysis access. *Journal of Vascular Access, 19*(3), 1129729817747535. doi:10.1177/1129729817747535.

National Kidney Foundation Kidney Disease Outcomes Quality Initiative (NKF-K/DOQI) (2006). Clinical practice guidelines for vascular access: Update 2006. *American Journal of Kidney Diseases, 48*(Suppl. 1), S176–S247.

Roy-Chaudhury, P. (2005). Endothelial progenitor cells, neointimal hyperplasia, and hemodialysis vascular access dysfunction: Novel therapies for a recalcitrant clinical problem. *Circulation, 112*(1), 3–5. doi:10.1161/circulationaha.105.548651

Roy-Chaudhury, P., Arend, L., Zhang, J., Krishnamoorthy, M., Wang, Y., Banerjee, R., ... Munda, R. (2007). Neointimal hyperplasia in early arteriovenous fistula failure. *American Journal of Kidney Diseases, 50*(5), 782–790. doi:https://doi.org/10.1053/j.ajkd.2007.07.019

Roy-Chaudhury, P., Spergel, L.M., Besarab, A., Asif, A., & Ravani, P. (2007). Biology of arteriovenous fistula failure. *Journal of Nephrology, 20*, 150–163.

Schoch, M., Du Toit, D., Marticorena, R.M., & Sinclair, P.M. (2015). Utilising point of care ultrasound for vascular access in haemodialysis. *Renal Society of Australasia Journal, 11*(2), 78–82.

Tuka, V., Wijnen, E., van der Sande, F.M., & Tordoir, J.H. (2009). Dialysis needle hemodynamics in arterio-venous fistulae: A technical report. *Journal of Vascular Access, 10*(3), 157–159.

Unnikrishnan, S., Huynh, T.N., Brott, B.C., Ito, Y., Cheng, C.H., Shih, A.M., ... Anayiotos, A.S. (2005). Turbulent flow evaluation of the venous needle during hemodialysis. *Journal of Biomechanical Engineering, 127*(7), 1141–1146.

van Loon, M.M., Kessels, A.G., van der Sande, F.M., & Tordoir, J.H. (2009). Cannulation and vascular access-related complications in hemodialysis: Factors determining successful cannulation. *Hemodialysis International, 13*(4), 498–504.

Yang, L., Yin, A., & Liu, W. (2017). Variation of flow rate and angle of injected venous needle on influencing intimal hyperplasia at the venous anastomosis of the hemodialysis graft. *Australasian Physical & Engineering Sciences in Medicine, 40*(1), 239–248. doi:10.1007/s13246-017-0526-6